

THE SAN DIEGO KNEE CLINIC

**Platelet-Rich Plasma & Hyaluronic Acid
Injections for Knee Osteoarthritis**

We will be offering counseling on diet and exercise. If interested, please contact my office and schedule a medically supervised *Health and Orthopedic Fitness* assessment appointment which will include a spine and joint health assessment evaluation. This assessment will not be covered by health insurance.

G. Charles Roland, M.D.
Director of The San Diego Knee Clinic
Orthopedic, Arthroscopic and Reconstructive Surgery
Diplomate of the American Board of Orthopedic Surgeons
Fellow of the American Academy of Orthopedic Surgeons
San Diego Knee & Sports Medicine Fellowship

Arthritis is one of the most chronic causes of joint disorder. More than 42 million people in the United States are diagnosed with arthritis. Among the most common types of arthritis are: **osteoarthritis (OA)**, **rheumatoid arthritis (RA)**, **hypertrophic arthritis**, **psoriatic arthritis (PsA)**, **fibromyalgia** and **gout**. The purpose of this paper is to reassess THE current literature outlining the onset and available treatment options for patients with knee arthritis pathology.

The Harvard Clinical and Translational Science Center describes **osteoarthritis (OA)** as a progressive degenerative joint disorder. The normal joint articular cartilage is a protective surface membrane found diffusely at the joint surfaces, which provides support and lubrication for healthy knee function. In OA kinematic and biomechanical changes affect the articular cartilage, causing subchondral bone remodeling (bone cysts, bone collapse, etc), degeneration of menisci and ligaments, synovial and osteophytic (bone) enlargement and joint capsular hypertrophy. All of which are associated with OA pathogenesis (Harvard, 2017). When the joint articular cartilage covering the bones of the knee wears away, it leaves bare bones in contact with each other causing mild to severe unremitting pain and swelling.

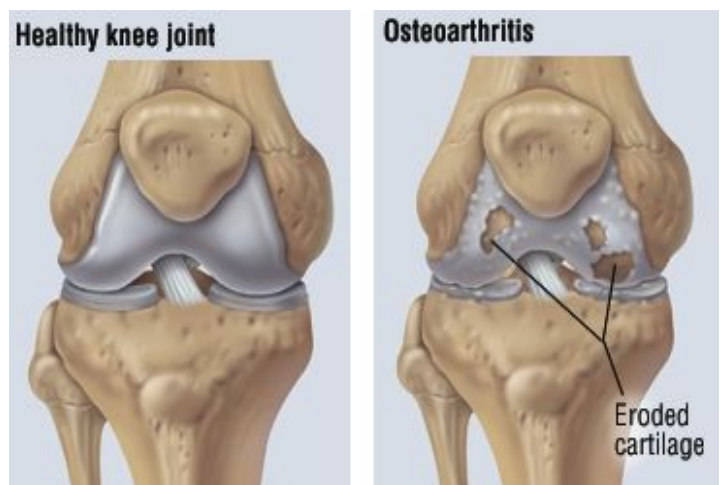


Image 1: Normal Knee and Osteoarthritis. Harvard University Press

Rheumatoid arthritis (RA), as defined by the Mayo Clinic team, is a chronic autoimmune disease that causes joint inflammation, pain, stiffness and swelling. RA can also alter the patient's joint(s), damage eyes, heart, lungs, and skin among other variety of bodily systems. RA is associated with joint deformity, and in cases of dramatic inflammation it is linked to physical disability.

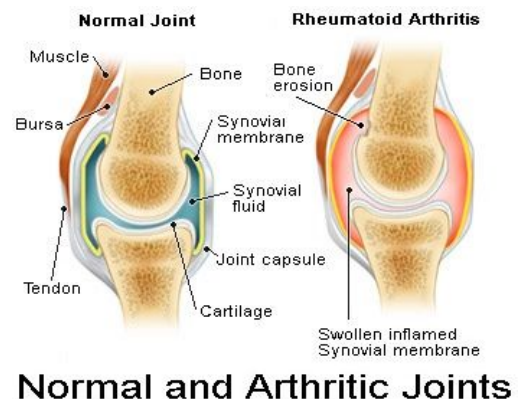


Image 2: Normal Knee and Rheumatoid Arthritis. Mayo Clinic Press

The normal knee follows a circular hinge motion, the bones in the upper and lower leg move in harmony while separated by the two shock-absorbing meniscii (semi lunar cartilages). The joint is lubricated with synovial fluid. The synovial fluid is generated by the inner lining membrane, called the synovial membrane. The normal knee is composed of the femur (thigh bone), patella (knee-cap), tibia (shin bone) inclusive of the healthy articular cartilage lining, found on the interior surfaces of the knee. The synovium is a soft multifunctional vascular membrane found on the interior surface of the interior of the knee producing synovial fluid for joint lubrication (see synovial fluid article).

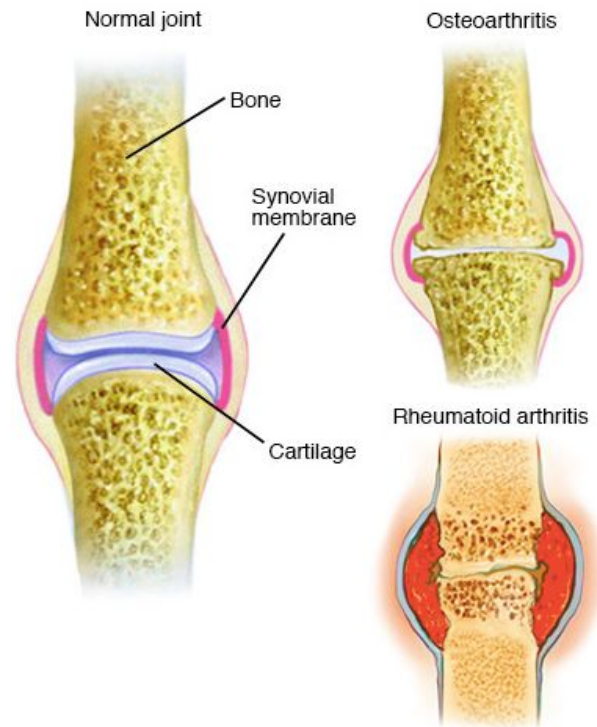


Image 3: Normal Knee, Osteoarthritis and Rheumatoid Arthritis. Mayo Clinic

At the initial exam a thorough knee workup is performed and includes the following: a complete history including the date of onset, location, causation, with a detailed description of injury. A detailed knee physical examination is performed along with x-rays, special laxity movement studies, and potentially a MRI will lead to a diagnosis prior to any form of treatment instituted. Occasionally, unusual diagnosis are discovered and treated accordingly.

Nevertheless, once a correct diagnosis is made, most knee patients only need instruction in an appropriate exercise and strengthening program with modification of activity. Invasive procedures, including biologics injections or surgery are reserved till conservative treatment has failed unless a severe mechanical problem is found, ie locking, catching, giving away, and chronic swelling and pain. However, well over 50% of knee patients will not even require an MRI unless the injury is severe or chronic.

Osteoarthritis

The word “osteoarthritis” (OA) originates from Greek language with the following meaning: “*osteon*” means “of the bone”, “*arthron*” meaning “joint”, and “*itis*” meaning “inflammation”. OA is the most common form of arthritis affecting the aging population, generating functional disability worldwide (Fox, 2009). Albeit cartilage collagen damage is the hallmark of OA, bone cysts, synovitis, hypertrophy of the joint capsule contribute to OA pathogenesis (Martel-Palletier, 2008). For knee OA treatment conservative pharmacologic modalities are prescribed in conjunction with non-pharmacological treatment modalities customized to individual patient’s needs. Specifically, paracetamol, non-steroid anti-inflammatory medications such as Aspirin, Motrin, opioids, and slow acting agents such as glucosamine and chondroitin sulfate (Ayhan, 2014). Cold packs are recommended to help reduce inflammation and pain associated with arthritis.

The conservative treatments for knee OA and mild injuries include physical exercises, weight reduction, walking support (crutches), analgesics, and non-steroidal anti-inflammatory agents. In cases when the orally administered treatments are inefficient, newer techniques of intra-joint injections (IA) are introduced, including **platelet rich plasma (PRP)**, **viscosupplementation (HA)**, **corticosteroids**, and potentially **stem cells** as final nonoperative modalities. This paper is a systematic review of PRP and HA literature on most recent clinical trials and examples from clinical practice.

Platelet rich plasma (PRP)

PRP is a concentration of blood platelets and growth factors obtained from the patient’s own blood using centrifugation techniques can be utilized immediately for clinical use. As there is evidence that PRP may accelerate the healing of residual tendon and meniscus tears. **Platelets** consist of proteins, cytokines, and other bioactive factors located in the peripheral blood. They contribute to the regulation of homeostasis and promote wound repair. **Plasma** contains clotting factors, proteins and ions. Recent literature suggests that for an optimal therapeutic purposes physicians should use a platelet concentration of 1 million platelets per microliter with a 3- to 5-fold increase in growth factor concentration and cytokines” (Mehta, 2008). In the plasma, numerous proteins are contained, such as insulin-like growth factor IGF, platelet-derived growth factor (PDGF), platelet factor interleukin (IL), platelet-derived angiogenesis factor (PDAF), epidermal growth factor (EGF), transforming growth factor (TGF), vascular endothelial growth factor (VEGF), and fibronectin (Lubkowska, 2012). Such anabolic growth factors inhibit inflammation and pain, as well as enhance the cartilage and bone

matrix biosynthesis (Brandl, 2010). In the dense granules of platelets such bioactive factors are also found, specifically calcium, dopamine, serotonin, histamine, and adenosine. Such non-growth bioactive factors control inflammation, proliferation, and remodeling in the process of wound healing (Boswell, 2012). PRP is also used in an attempt to slow down the arthritic degeneration process, preserve chondrocytes which are cartilage cells that line the joint. PRP also stimulates ligament, tendon tissue repair, and meniscal healing. Italian scientist in 2010 conducted a clinical trial with 3 sets of intra-articular PRP injections in a 21-days intervals to 115 patients with knee osteoarthritis pathology. Statistically significant results were observed at 6- and 12 months time-period (Kon, 2010). The experiment showed that patients when receiving 3 sets of intra articular PRP injections at 21 day intervals reported best results of improvement at 6- and 12 months of follow-up period (Kon, 2010).

Similarly, Smith and colleagues performed a Food and Drug Administration-sanctioned clinical trial investigating the effect of intra-articular leukocyte-poor PRP autologous conditioned plasma (ACP) and compared to saline placebo in 30 knee OA patients. Smith discovered the PRP treated group had an overall 78% improvement compared to 7% in placebo group evaluated on WOMAC score (Smith, 2016).

In the debate whether fresh PRP versus cryopreservation (freezing at -80 C) PRP is more effective, the literature supports fresh PRP (Blajchman, 2001). Storing/freezing platelets may degranulate the alpha granules and as a result, lower the functional properties of the platelets. Moreover, Roffi and his colleagues observed a decrease in protein level in frozen thawed PRP. Nevertheless, he concluded that frozen PRP and fresh PRP are equal in ability to produce Extra Cellular Matrix (ECM) particles in synoviocytes and chondrocytes (Roffi, 2014).

This systematic review of the literature for PRP techniques summarizes the effectiveness of PRP in pain management, reduction in inflammation, improvement in joint function and potentially cartilage regeneration. PRP blood products carry large quantities of concentrated growth factors and biologically active molecules required for effective and affordable treatment of OA onset and progression of the disease process (Ayhan, 2014). The low cost, safety, simple preparation technique promotes the high acceptance of the PRP technique into the clinical realm in the treatment of OA.

Currently health insurance coverage does not pay for PRP treatment. We will discuss various payment options to receive this treatment if it is felt to be advantageous to your condition(s).

❖ **PRP and Meniscus repair**

German and Swiss scientists confirmed that PRP percutaneous injections releases therapeutic properties for pain relief and promote the decrease in grade 2 meniscal lesions progression in patients over the 6 months time period (Blanke, 2015).

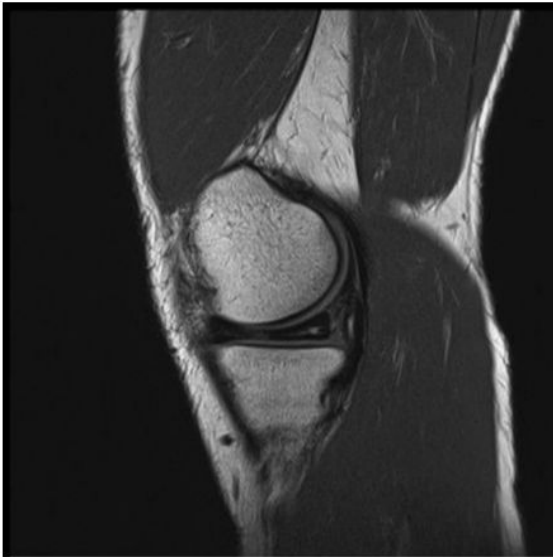


Figure 1. Meniscal lesion before injections (patient 7).

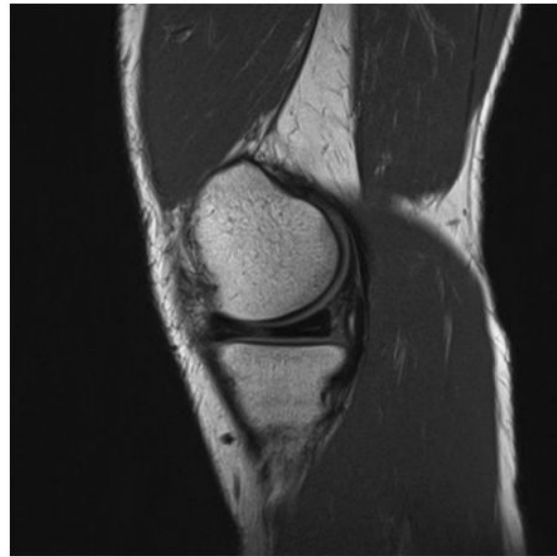


Figure 2. Meniscal lesion 6 months after injections (patient 7).

Source: Blanke, F., *Percutaneous injections of Platelet Rich Plasma for treatment of intrasubstance meniscal lesions*. *Muscles, Ligaments and Tendons Journal* 2015;5 (3):162-166

Another study on animals treated with PRP injections for meniscal tissue defects revealed the potential for healing of PRP at the inner, avascular part of the meniscus. Subjects treated with PRP showed significantly greater scores for the number of fibro-chondrocytes and the production of extracellular matrix compared to the control group (Ishida, 2007). Moreover, several studies suggest the additive effect of PRP-containing growth factors for increased meniscal cell activity and produced an augmentation of meniscal repair and healing of horizontal cleavage meniscal tears repaired via an open surgery. A team of surgeons from France in one such study invited 17 patients for open meniscal repair surgery of horizontal tears extending into the avascular zone—Group 1, and additional 17 patients for the same surgery with addition of PRP injections at the end of the open meniscal repair—Group 2 (Pujol, 2014).

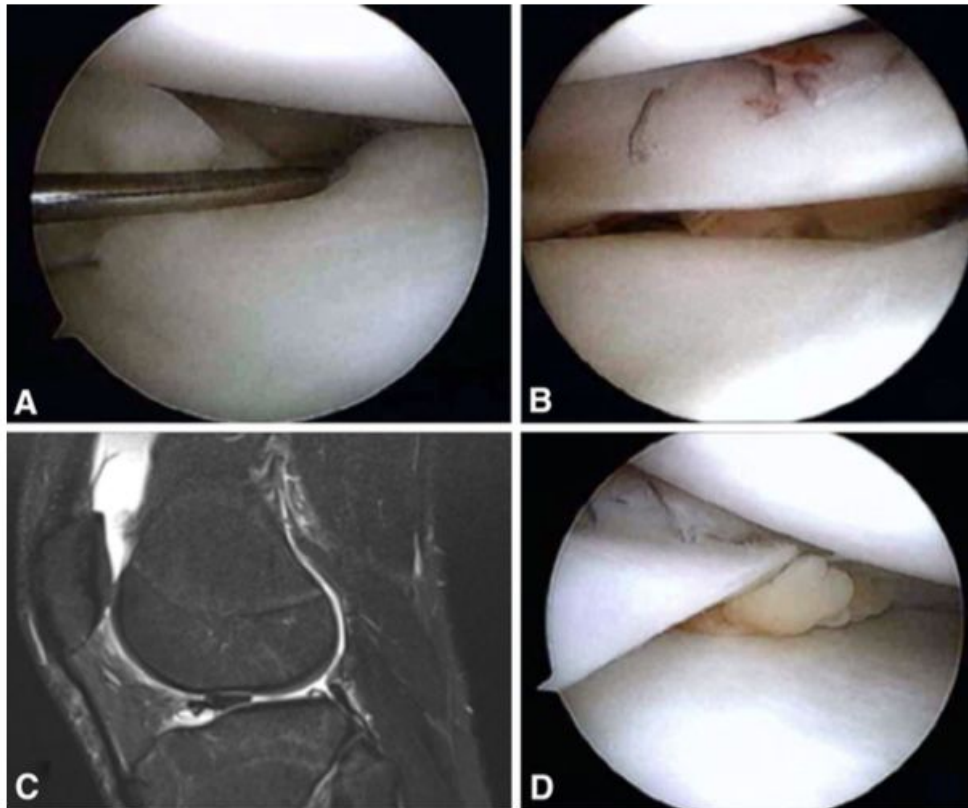


Fig. 1A–D (A) An intraoperative image of a displaced meniscus tear is shown. (B) An inside-out repair is performed with PRP augmentation. (C) MRI demonstrates a bucket-handle lateral meniscus tear and (D) PRP augmentation of this meniscus repair.

Source: Griffin, J.W., et al. *Platelet-rich Plasma in Meniscal Repair: Does Augmentation Improve Surgical Outcomes?* *Clinical Orthopedics and Related Research*. 2015. 472: 1665-1672.

The MRI results of this study demonstrated that 5 patients from Group 2 had full disappearance of hypersignal within the repaired meniscus at the 24 months postoperative time-frame (De Chou, 2015). Such evidence suggest the additive effect of PRP to improve outcome results after open meniscal repair surgery. Due to patient’s individual meniscal injury variations, PRP can be injected in the knee at the time of surgery or fairly soon after surgery. Meta-analysis of PRP technology confirms that PRP treatment promotes more robust healing in an attempt to preserve the meniscus tissue and to provide faster and better healing of the residual meniscus and knee joint tissues, including the ACL and PCL ligaments.

The use of PRP technology in musculo-skeletal conditions treatment has become more prevalent in recent years. PRP is rich in growth factors, proteins, cytokines, and other cellular components required for the body’s healing response to injury.

A systematic review of the scientific literature suggests the effectiveness of PRP injections in treating mild to moderate knee osteoarthritis, elbow ulnar collateral ligament (UCL) tears, epicondylitis (tennis elbow), knee meniscus tear, partial rotator cuff tears, achilles tendinopathy, and tendon injuries (Ryan, 2016).

Hyaluronic Acid (HA) Injections

- ❖ **Viscosupplementation** is a method where hyaluronic acid (HA) is injected into the knee joint to manage OA pathology by restoring more normal joint lubrication by improving synovial fluid viscosity.
- ❖ HA is also used in post-surgery cases after corrective surgery or in non-surgical cases in an attempt to reduce arthritis-associated pain. Surgical cases include altered joint mechanics secondary to injury that stimulate mechanical complaints with associated stiffness, instability, locking, catching, swelling, as well as chronic and progressive pain (Halpern, 2012).

Hyaluronate or hyaluronan is contained in cartilage and the synovial fluid. HA is a large viscoelastic glycosaminoglycan molecule that is contained in synovial fluid and cartilage matrix. Chondrocytes (cartilage cells), fibroblasts (collagen producing cell) and the synovial cells all secrete HA into the joint.

The HA approved by the The Food and Drug Administration (FDA) is either generated from bacterial fermentation in vitro or from harvested rooster combs. Such HA contains Hylan G-F 20, sodium hyaluronate, and high-molecular weight hyaluronan (McArthur, 2012). In healthy patients the synovial fluid contains a normal HA concentration and serves as a viscous lubricant for healthy knee movements, much like a lubricant in a car. In OA patients the synovial inflammation contained in proteases, free radicals, cytokines leads to the disruption of organic HA synthesis and contributes toward the progression of OA (Brockmeier, 2006). A healthy level of HA is crucial in projecting anti-inflammatory properties to regulate cartilage homeostasis, to slow the chondrocyte apoptosis (ie cartilage cell death) since there is a decreased amount of HA in the synovial fluid of OA patients (Trigkilidas, 2013).

Although there is a plethora of supporting literature of the HA injections beneficial effect, one report published in the *Annals of Internal Medicine* suggested that many patients are made worse by hyaluronic acid injections (Rutjes, 2012). The conclusion of the study was that HA injections are often performed by non-knee fellowship-trained physicians or physician's assistant without extensive experience in complex knee injury cases and little in-depth understanding of the anatomy and internal knee biomechanics

and kinematics. Another report in the *Techniques in Regional Anesthesia and Pain Management* stated that: "Complications of knee injections have been related to pain or swelling at the site of injection: granulomatous inflammation of the synovium, saphenous neuropathy, aseptic acute arthritis, septic arthritis, embolia cutis medicamentosa (Nicolau Syndrome), and albicans arthritis" (Cheng, 2007).

In contrast, another report from University of Warwick, UK revealed minor yet positive statistically significant results from several studies performed with randomised 110 participants within 3 groups: placebo, hyaluronic injections, and steroid injections. The group treated with 20 mg triamcinolone hexacetonide (TH) steroid IA injections exhibited superior results during the first four weeks of treatment (Jones, 1995), while the HA group participants showed superiority during the 4-8 weeks timeframe (Trigkilidas, 2013).

Thus the implication of both steroid injections and hyaluronic injections presented a positive synergistic effect during the long-term treatment.

"I am hesitant in providing steroid injections intra articular since I am concerned about the potential harmful effects of steroid injections inside the joint. I will provide these injections in end stage arthritic disease as an attempt to forestall the need for artificial joint replacements. I will also use the HA injections in more serious arthritic conditions in an attempt to decrease symptoms prior to a total knee replacement. An extensive waiting period after intra joint injections is required prior to performing a total knee replacement in an attempt to avoid operative infections"- **G. Charles Roland, MD**

In summary, the systematic review of current literature suggest that hyaluronic injections exhibit a safe and at best a modest effect for the mild OA treatment up to 24 weeks (Bannuru, 2011).

❖ **PRP versus HA injections**

Dai and his colleagues in China studied PRP, HA, and saline differences confirming that intra-articular PRP injections promote greater pain relief and better functional improvement in knee OA patients at 1 year post-injection period. During the experiment it was discovered that HA and PRP similarly relieved pain and improved functional activity as evaluated by the McMaster Universities Osteoarthritis Index (WOMAC) pain and function score. Nevertheless, at 12 months postinjection PRP presented with

superior results (Dai, 2016). Studies performed by Spakova indicate that PRP in 120 patients showed positive statistically significant results compared to the participants receiving hyaluronic acid (HA) injections (Spakova, 2012). Another study of HA to PRP by Say confirmed superior benefits of PRP in addition to a higher safety score and increased affordability for OA treatment (Say, 2013).

Campbell from Chicago Medical Center published a review comparing intra-articular injections of PRP versus HA or placebo in 3278 patient knees (Campbell, 2015). The results of the study revealed the superior outcome in the PRP group at 2 to 12 months postinjection. Three other Level 1 studies have verified that PRP exhibits superior anti-inflammatory and pain relief properties when compared to HA injections (Sanches, Cerza, 2012) or to placebo-controlled cases (Patel, 2013). Another study by Cole and colleagues comparing the clinical and biological effects of PRP and HA injections in OA patients confirmed the superior benefits of PRP at 24 and 52 weeks when compared to HA intra-articular injections as evaluated on the visual analog scale (VAS).

In the same study it was determined that low Body Mass Index (BMI) ($<24 \text{ kg/m}^2$) notably impacted patient-reported outcomes in contrast to high BMI ($>34 \text{ kg/m}^2$). The team concluded that HA and PRP proved to be a superior treatment technology for low to moderate OA patients (Cole, 2016). As defined in the Journal of Public Health, BMI is the person's weight (in kilograms) divided by height (in metres) squared. Since both of the parameters are easily measured, BMI from the end of 18th century became a popular heuristic approximation for body fatness in clinical practice (Eknoyan, 2008). "The World Health Organization defined that according to BMI calculations individuals are categorized as underweight (BMI $< 18.5 \text{ kg/m}^2$), normal weight ($18.5\text{--}24.9 \text{ kg/m}^2$), overweight ($25.0\text{--}29.9 \text{ kg/m}^2$) and obese ($\geq 30.0 \text{ kg/m}^2$) fatness categories (World Health Organization, 2000). Obesity and overweight results in 3 million deaths each year, due to dramatic increase of risk factor for mortality and morbidity from incident cancer, cardiovascular disease, type 2 diabetes, and other diseases (Sperrin, 2016).

There were many limitations identified throughout the process of reviewing the medical literature. Specifically, the search of relevant material was limited to articles available only in English, studies only performed primarily on humans, and articles only available electronically. Only data already published was cited, excluding promising preliminary studies. Another limitation is that only papers with full text available from University of California San Diego library or Google Scholar were retrieved, cited, and analyzed.

References:

Brockmeier SF, Shaffer BS. Viscosupplementation therapy for osteoarthritis. *Sports Med Arthritis* 2006; 14: 155-162.

Bannuru RR, Natov NS, Dasi UR, Schmid CH, McAlindon TE. Therapeutic trajectory following intra-articular hyaluronic acid injection in knee osteoarthritis—meta-analysis. *Osteoarthritis Cartilage* 2011; 19:611-619.

Brandl A., Angele P., Roll C., et al. *Influence of the growth factors PDGF-BB, TGF-beta1 and bFGF on the replicative aging of human articular chondrocytes during in vitro expansion.* *J Orthop Res.* 2010; 28(3): 354-360.

Chubinskaya S., Hurtig M., Rueger DC., *OP-1/BMP-7 in cartilage repair.* *Int Orthop.* 2007; 31(6): 773-781.

Ballamy N, Campbell J, Robinson V, Gee T, Bourne R, Wells G. Viscosupplementation of the treatment of osteoarthritis of the knee. *Cochrane Database Syst Rev* 2006; (2).

Hall MP, et al, Platelet-rich plasma: current concepts and application in sports medicine. *J Am Acad Orthop Surg* 2009; 17: 602-608.

Cole, B.J., Karas, V., Hussey, K., Pilz, K., Fortier, L.A. *Hyaluronic Acid Versus Platelet-Rich-Plasma. A Prospective, Double-Blind Randomized Controlled Trial Comparing Clinical Outcomes and Effects on Intra-articular Biology for the Treatment of Knee Osteoarthritis.* *The American Journal of Sports Medicine.* 2016. 45; 2, 2017

Kon E., et al, Platelet-rich plasma: intra-articular knee injections produced favorable results on degenerative cartilage lesions. *Knee Surg Sports Traumatol Arthrosc* 201; 18: 472-479

Ayhan, E., et al. Intraarticular injections (corticosteroid, hyaluronic acid, platelet rich plasma) for the knee osteoarthritis. *World Journal of Orthopedics.*, 2014. 18; 5(3): 351-361. Web.

Bannuru, RR., et al. Therapeutic trajectory following intra-articular hyaluronic acid injection in knee osteoarthritis—meta-analysis. *Osteoarthritis Cartilage* 2011. 19: 611-619. Web

Lubkowska, A., et al. Growth factor content in PRP and their applicability in medicine. *Journal of Biological Regulators and Homeostatic Agents*. 2012. 26: 3S-22S. Web

Fox BA, Stephens MM. Glucosamine/chondroitin/primorine combination therapy for osteoarthritis. *Drugs Today (Barc)* 2009;45(1):21–31. Web.

Spakova, T., et al. Treatment of knee joint osteoarthritis with autologous platelet-rich plasma in compasicon with hyaluronic acid. *American Journal of Physical Medicine and Rehabilitation*. 2012. 91: 411-417. Web.

Say, F., et al. Platelet-rich plasma injection is more effective than hyaluronic acid in the treatment of the knee osteoarthritis. *Acta chirurgiae orthopaedicae et traumatologiae Cechoslovaca*. 2013. 80: 278-283. Web.

Kon, E., et al. Platelet-rich plasma: intra-articular knee injections produced favorable results on degenerative cartilage lesions. *Knee Surgery, Sports Traumatology, Arthroscopy*. 2010. 18: 472-479. Web.

Patel, S., et al. Treatment with platelet-rich plasma is more effective than placebo for knee osteoarthritis: a prospective, double-blind, randomized trial. *American Journal of Sports Medicine*. 2013. 41: 356-364. Web.

Sanchez, M., et al. A randomized clinical trial evaluating plasma rich in growth factors (PRGF-Endoret) versus hyaluronic acid in the short-term treatment of symptomatic knee osteoarthritis. *Arthroscopy*. 2012. 28: 1070-1078. Web.

Cerza, F., et al. Comparison between hyaluronic acid and platelet rich plasma, intra-articular infiltration in the treatment of gonarthrosis. *American Journal of Sports Medicine*. 2012. 40: 2822-2827. Web.

Roffi, A., et al. Does platelet-rich plasma freeze-thawing influence growth factors release and their effects in chondrocytes and synoviocytes? *Biomed Research Initiative*. 2014. 692913.

Lamo-Espinosa, J. M., Mora, G., Blanco, J. F., Granero-Moltó, F., Nuñez-Córdoba, J. M. Sánchez-Echenique, C., Bondía⁸, J. M., Aquerreta, J.D., Andreu, E. J., Ornilla⁹, E., Villarón, E. M. Valentí-Azcárate, A., Sánchez-Guijo, F., Consuelo del Cañizo, M., Valentí-Nin, J. R., and Prósper, F. *Intra-articular injection of two different doses of autologous bone marrow mesenchymal stem cells versus hyaluronic acid in the treatment of knee osteoarthritis: multicenter randomized controlled clinical trial (phase I/II)*. *Journal of Translational Medicine*. (2016) 14:246.

Gupta, P.K., Das, A.K., Chullikana, A., Majumdar, A.S. *Mesenchymal stem cells for cartilage repair in osteoarthritis*. Stem Cell Research and Therapy. 2012. 3:25.

Boswell SG, Cole BJ, Sundman EA, KAras V., Fortier LA *Platelet-rich plasma. A milieu of bioactive factors*. Arthroscopy 2012;28:429-439.

Pujol, N., De Chou, E.S., Boisrenoult, P., Beaufils, P., *Platelet-rich plasma for open meniscal repair in young patients: Any benefit?* Knee Surgery, Sports Traumatology, Arthroscopy. (2014) 23: 51. doi:10.1007/s00167-014-3417-3

Ishida K., Kuroda R., Miwa M. *The regenerative effects of platelet-rich plasma on meniscal cells in vitro and its in vivo application with biodegradable gelatin hydrogel*. Tissue Eng. 2007;13:1103-1112.

Lubkowska, A., Dolegowska, B., Banfi, G. *Growth factor content in PRP and their applicability in medicine*. J Biol Regul Homeost Agents. 2012 Apr-Jun;26(2 Suppl 1):3S-22S. Web. <https://www.ncbi.nlm.nih.gov/pubmed/23648195>

Mehta, S., Watson, JT. *Platelet-rich concentrate: Basic science and clinical applications*. J Orthop Trauma 2008; 22:432-438.

Griffin, J.W., et al. *Platelet-rich Plasma in Meniscal Repair: Does Augmentation Improve Surgical Outcomes?* Clinical Orthopedics and Related Research. 2015. 472: 1665-1672.

Blanke, F., *Percutaneous injections of Platelet Rich Plasma for treatment of intrasubstance meniscal lesions*. Muscles, Ligaments and Tendons Journal 2015;5 (3):162-166

Martel-Palletier J, et al, *Cartilage in normal and osteoarthritic conditions*. Best Pract Res Clin Rheumatol 2008. 22: 351-384.

McArthur, BA., et al. *Long term safety, efficacy, and patient acceptability of hyaluronic acid injection in patients with painful osteoarthritis of the knee*. Patient Prefer Adherence 2012; 6: 905-910. Web.

Sarabi, Z.S., Afshari, J.T., Ghassemi, A., Yaghobi, M., *Mesenchymal stem cell and osteoarthritis: a literature review*. Reviews in Clinical Medicine. 2016; Vol 3 (No 2). 84-86. Web. http://rcm.mums.ac.ir/article_6830_900.html

Trigkillidas, D., Anand, A. *The effectiveness of hyaluronic acid intra-articular injections in managing osteoarthritic knee pain*. 2013. *Annals of The Royal College of Surgeons of England*. 95: 545-551.

Uth, K., Trifonov, D. *Stem cell application for osteoarthritis in the knee joint: A minireview*. *World Journal of Stem Cells*. 2016. 6(5): 629-636. Web.
<https://www.ncbi.nlm.nih.gov/pmc/articles/PMC4178263/>

Wyles, C.C., Houdek, M.T., Behfar, A., Sierra, R.J. *Mesenchymal stem cell therapy for osteoarthritis: current perspectives*. *Stem Cells and Cloning: Advances and Applications* 2015;8 117–124. Web. <https://www.ncbi.nlm.nih.gov/pmc/articles/PMC4559256/>

Dai, W., Zhou, A.G., Zhang, H., Zhang, J. *Efficacy of Platelet-Rich Plasma in the treatment of Knee Osteoarthritis: A Meta-analysis of Randomized Controlled Trials*. *Arthroscopy: The Journal of Arthroscopy and Related Surgery*, 2016: 1-12.

Campbell, KA., Saltzman BM., Mascarenhas R., et al. Does intra-articular platelet-rich plasma injection provide clinically superior outcomes compared with other therapies in the treatment of knee osteoarthritis? A systematic review of overlapping meta-analyses. *Arthroscopy*. 2015; 31(11).

Smith PA. Intra-articular autologous conditioned plasma injections provide safe and efficacious treatment for knee osteoarthritis; An FDA-sanctioned, randomized, double-blind, placebo-controlled clinical trial. *Am J Sports Med*. 2016; 44(4): 884-891.

Eknoyan, G. Adolphe Quetelet (1796–1874) - the average man and indices of obesity. *Nephrol Dial Transplant*. 2008; 23:47–51.

World Health Organization. *Obesity: preventing and managing the global epidemic. Report of a WHO Consultation (WHO Technical Report Series 894)*. Geneva: World Health Organization 2000.

Sperrin, M., Marchall, A.D., Higgins, V., Renehan, A.G., Buchan, I.E., Body mass index relates weight to height differently in women and older adults: serial cross-sectional surveys in England (1992–2011). *J Public Health (Oxf)* (2016) 38 (3): 607-613.

Mlynarek, R. A., Kuhn, A. W., Bedi, A. Platelet-Rich Plasma (PRP) in Orthopedic Sports Medicine. *The American Journal of Orthopedics*. 2016; 45(5):290-294, 326