
THE SAN DIEGO KNEE CLINIC

**Understanding the Anatomy
and Function of the Knee**

We will be offering counseling on diet and exercise. If interested, please contact my office and schedule a medically supervised *Health and Orthopedic Fitness* assessment appointment which will include a spine and joint health assessment evaluation. This assessment will not be covered by health insurance.

G. Charles Roland, M.D.
Director of The San Diego Knee Clinic
Orthopedic, Arthroscopic and Reconstructive Surgery
Diplomate of the American Board of Orthopedic Surgeons
Fellow of the American Academy of Orthopedic Surgeons
San Diego Knee & Sports Medicine Fellowship

Abstract

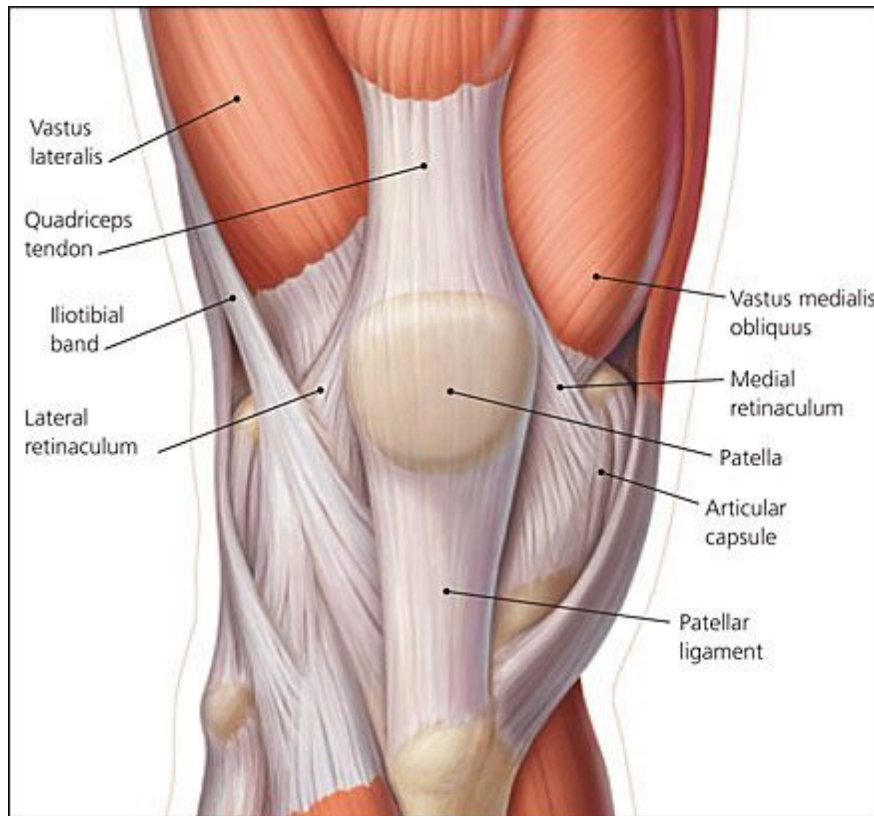
The knee joint, formed by the distal femur and the proximal tibia, is the largest and most complicated synovial joint in the body. Because of its unique positioning—between the body’s two longest mechanical levers—the knee is subject to a significant number of sports-related injuries. Injuries can result from acute traumatic, subacute, or chronic overload situations in the proximity of the knee. The management of each condition presents unique challenges. In this article the anatomy and function of the knee joint are outlined.

The knee joint, formed by the distal femur and the proximal tibia, is the most complicated and largest synovial joint in the body. A comprehension of the normal anatomy of the knee joint is essential to understanding the mechanism of injury. Several mechanisms interrelate to provide stability. Function of this joint is dependent upon its complexity, as well as upon the simplicity of a hinge joint. The arrangement of the osseous and soft tissues around the knee joint permit minimal rotation, as well as flexion and extension.

Other osseous structures associated with the knee joint are the patella and the fibula. The patella, which is located distally to the quadriceps tendon and anterior to the knee joint, is the body’s largest sesamoid bone. The fibula is situated lateral to the tibia and is not intimately involved with the knee joint; the fibula and the tibia comprise a second joint.

The following provides an overview of the structural anatomy of the knee and relates this information to its functional anatomy. The complexity of the knee is demonstrated by its anatomy. The capsule of the knee envelops the synovial cavity, and, in turn, is supported by various bands and structures. The musculature of the thigh plays an integral role in both moving and supporting the knee joint. Semilunar cartilages, or menisci, permit a larger area of pressure distribution over the tibia. Ligaments interrelate with other structural aspects of the knee to provide stabilization, whereas bursae and synovium enhance movement and reduce friction (FIGURE 1).

Figure 1: Structural Anatomy of the Knee Capsule

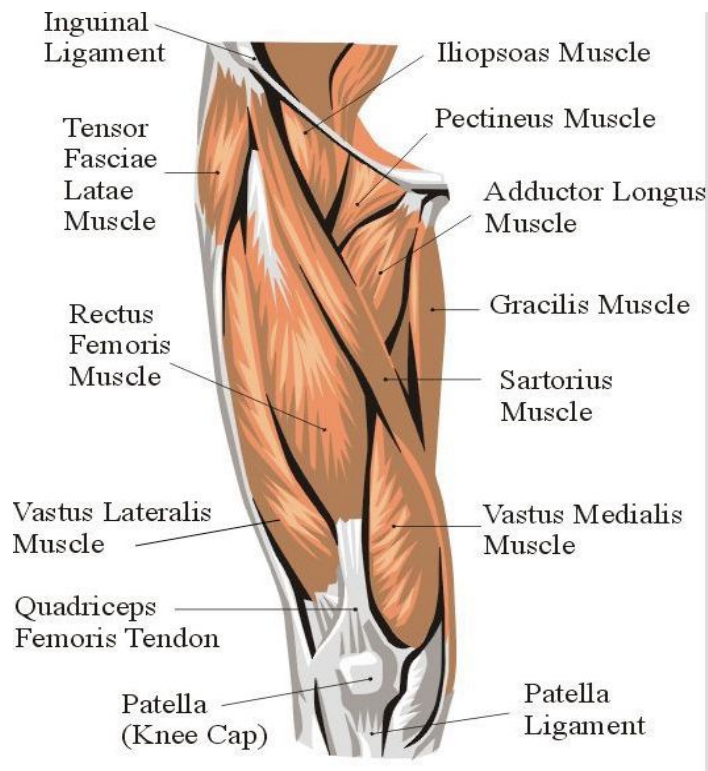


The capsule of the knee consists of a tough membrane of variable thickness, forming an envelope around the synovial cavity. Various bands and structures are connected to and associate with the capsule, helping to provide reinforcement. Anteriorly, the capsule is reinforced by an expansion from the fascia lata and the iliotibial band, which form the patellar retinacula. Posteriorly, the capsule consists of vertical fibers, situated behind the posterior cruciate ligament. The medial capsule is strengthened by expansions from the sartorius and the semimembranosus muscles. Lateral capsular reinforcement is derived for the iliotibial band, which fills the interval between the oblique popliteal ligament and the lateral collateral ligament. The medial and lateral compartments of the capsule are subdivided into the meniscotibial and meniscofemoral ligaments, extending from the menisci to the tibia and femur, respectively.

The musculature of the thigh has three major divisions: the anterior, medial, and posterior compartments. The quadriceps muscle group, including the three vastus

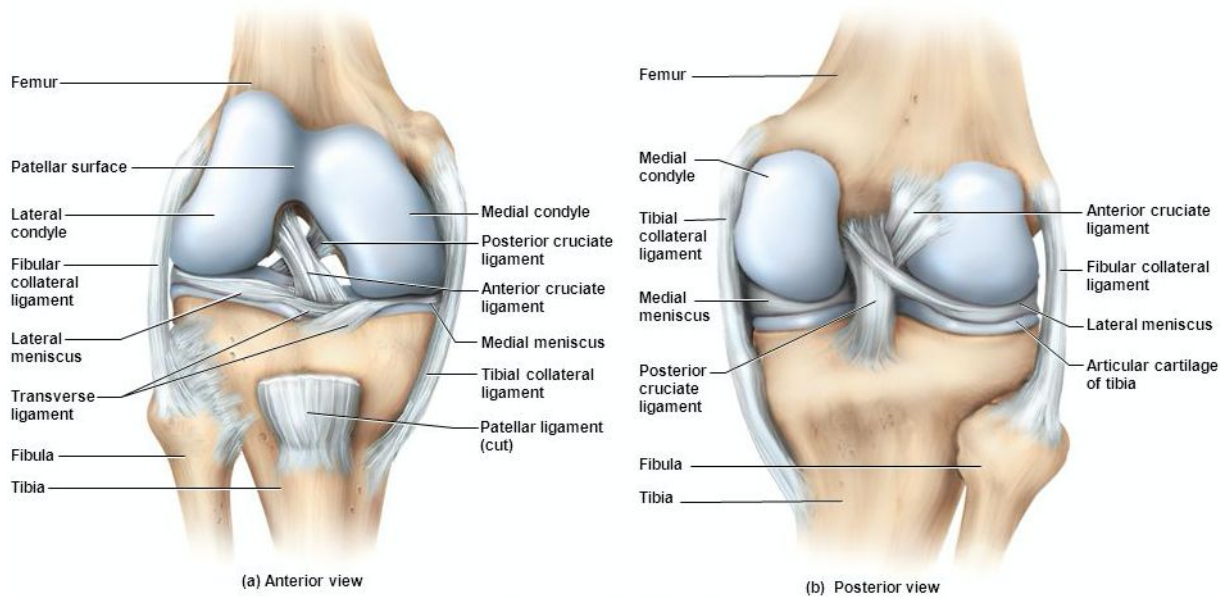
muscles—the lateralis, intermedius, and medialis, extending inferiorly from the trochanters—and the rectus femoris, which is anterior to the later three muscles in the middle of the thigh, extends over the anterior aspect of the femur. The quadriceps muscles unite at the distal thigh and insert into the apex of the patella.

Figure 2: Musculature of the Thigh



The patellar tendon, which can be considered to be a direct extension of the mechanism of the quadriceps, extends from the base of the patella to the tibial tuberosity.

The ribbon-like sartorius muscle is the longest of any muscle in the body. From its origin at the anterior superior iliac spine, it extends downward and medially, crossing the knee and inserting at the pes anserinus. The semimembranosus muscle also arises from the ischial tuberosity and extends down the posteromedial thigh to insert onto the medial condyle of the tibia.

Figure 3: Meniscal Structure within the Knee

The menisci, the semilunar cartilages, are intrasynovial structures, which deepen the fossae of the tibial plateau and, by virtue of the association with the femoral condyles, allow a larger area of pressure distribution over the tibia. Additionally, the menisci help to maintain smooth functioning of the knee joint by protecting the opposing articular surfaces through application of a thin nutrient film.^{5, 7-10}

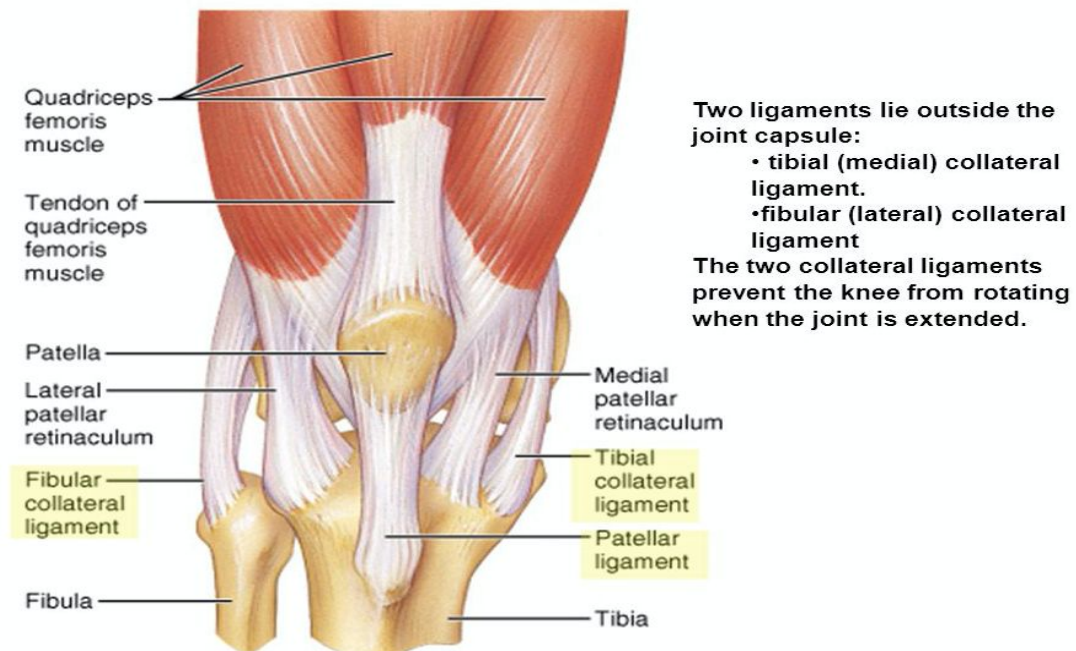
The medial meniscus is a C-shaped structure, and its periphery closely follows the medial tibial plateau. This meniscus is attached tightly to the joint capsule and the medial collateral ligament, which decreases mobility, making it more prone to injury than the lateral meniscus.¹¹

The lateral meniscus is wider than the medial meniscus, and, in appearance, is almost a closed circle. This meniscus is only loosely connected to the capsule. From alongside its posterior attachment to the tibia, the lateral meniscus gives off a strong fasciculus—the posterior menisiofemoral ligament, or ligament of Wrisberg, which inserts in the medial femoral condyle just behind the attachment of the posterior cruciate ligament. The transverse ligament extends between and connects the anterior ends of the menisci. The coronary ligaments connect the periphery of the menisci to the head of the tibia.

Microangiography shows the vascular supply of the menisci to be nonuniform. The outer one third to one half of the menisci have a rich vascular supply, whereas the innermost portions remain avascular.^{10,12,13}

Anastomoses exist between the anterior horns and the anterior cruciate ligaments, providing an abundant vasculature in these regions. Similar connections exist between the posterior horns and the posterior cruciate ligaments. The nature of this vascular network has obvious implications regarding attempts at repairing tears in certain regions of the menisci.

Figure 4: Ligamentous Structure of the Knee Joint



The four major ligaments of the knee are the medial (tibial) and lateral collateral ligaments (MCL and LCL, respectively) and the anterior and posterior cruciate ligaments (ACL and PCL, respectively). The MCL is a broad band, approximately 10 to 12 cm in length, extending from the medial femoral epicondyle and covering one third of the medial surface of the proximal tibia. This ligament consists of short, deep fibers posteriorly, which are further subdivided into deep meniscofemoral and meniscotibial portions, and a longer superficial ligament that is arranged in a flattened band anteriorly extending distally along the proximal tibia for a distance of at least 5 to 6 centimeters

distal to the medial joint. The LCL is a cordlike structure about 4 to 5 cm long, attached proximally to the lateral epicondyle of the femur, and inserts on the superolateral side of the fibular head.

The cruciate ligaments (Figure 3), so-called because of their crossed relationship, are situated in the middle of the joint. The relative positions, anterior and posterior, refer to their respective attachments to the tibia. The ACL arises from the anterior midsection of the tibial plateau, and extends superiorly, posteriorly, and laterally for approximately 3 to 4 cm, attaching posteriorly at the medial side of the lateral femoral condyle. The PCL attaches anteriorly in the intercondylar notch on the lateral side of the medial femoral condyle, and extends inferiorly, posteriorly, and laterally to insert in the posterior intercondylar fossa on the tibia.^{6,14,15}

The cruciate ligaments can be divided into separate anatomic and functional components. The ACL has two distinct bands. The bulk of the ligament lies posterolaterally, but there is also an anteromedial band or fascicle.

The PCL also consists of two sections: the anterior portion making up the bulk of the ligament and a smaller posterior portion. The femoral attachments of the ligaments are crescent-shaped with the concavity directed anteroinferiorly. Due to this configuration, the ligaments become twisted about the longitudinal axes during flexion.¹⁵

The oblique popliteal ligament,¹⁶ a flat, broad band, extends from the posterior surface of the lateral femoral condyle and sweeps inferiorly and medially to attach distally to the posteromedial surface of the lateral tibial plateau.

The arcuate ligament arises from the lateral aspect of the lateral femoral condyle to extend inferomedially to attach to the posterior capsule. Two bands connect this ligament to the styloid process of the fibula. In combination with the lateral collateral ligament and the popliteus muscle, the arcuate ligament forms the arcuate complex.⁴

SYNOVIUM AND BURSAE

The inner joint capsule is invested with a synovial lining that produces the lubricating and nutritive fluid for the joint. An extension of this sac extends superiorly from under

the patella to the distal quadriceps tendon, forming the suprapatellar pouch. A number of bursae are also located about the knee. These bursae are normally interposed between the skin and underlying structures to facilitate movement and reduce friction. The most commonly occurring bursae include the prepatellar, the deep and superficial infrapatellar bursae, and the pes anserine bursae.¹⁷

Knee stability is essential for ambulation. The functional stability of the knee is derived from passive and active restraints, as well as joint compressive forces and the geometry of the joint itself. Ligamentous structures may be the most important factors in providing stability.

Knee stability is of vital importance in ambulation. This functional stability is provided by the passive restraints of the ligaments, the geometry of the joint, active restraints by the musculature, and joint compressive forces that are generated with activity. The majority of the knee stability is derived from ligamentous structures. These stabilizing ligaments can be subdivided according to their relative contribution to joint stability as being either primary, secondary, or tertiary stabilizers.^{1,3,4,6,14,18} There is a primary stabilizing ligament for each plane of motion, and this ligament provides the most resistance to deformation in that plane. The secondary and tertiary stabilizers provide additional stability, depending on the position of the joint.

Because the primary stabilizer provides the most resistance to stress in a given plane, if this ligament is intact, then only minimal instability will exist in this plane, even if the secondary stabilizers are disrupted. The secondary and tertiary stabilizers provide variable amounts of resistance to deformation when the primary stabilizer is damaged. If the secondary and tertiary stabilizers are disrupted with the primary stabilizers, significant instability of the knee is created.

The configuration of the knee joint's articulating surfaces provides a small amount of inherent stability. The menisci deepen the fossae in the tibial plateaus and fill in the space between the surfaces of the femoral condyles and the tibial plateau. In

doing so, the menisci create a congruous articulation between the femoral and tibial condyles.

Dynamic stability is provided by the complex interaction of the musculature about the knee as it moves through its full range of motion. Compressive forces generated in the joint further stabilize the joint during activity. These joint reactive forces are maximal in an extended weight-bearing knee and vary markedly depending on the joint position.

Medially, the primary stabilizer is the superficial medial collateral ligament (MCL), which provides stability in all degrees of flexion. The contribution of the secondary stabilizers depends on position. These stabilizers, comprised of posterior oblique ligaments in addition to capsular reinforcement, the anterior cruciate ligament (ACL), and the posterior capsule, exert their greatest contribution in full extension. The clinical relevance of this arrangement is that even in the presence of a complete rupture of the MCL with intact secondary and tertiary stabilizers, the knee joint appears stable to valgus stress in full extension.³

Lateral stability at 30° of flexion is provided primarily by the lateral collateral ligament (LCL), in addition to some very closely associated secondary stabilizers, including the iliotibial band, which act in concert as a finely coordinated functional complex of muscles, tendons, and ligaments. At greater than 30° of flexion, stability is provided by the popliteal tendon and its dense aponeurosis, the arcuate ligament, and the ACL. The posterior cruciate ligament (PCL) can also act as a tertiary stabilizer, most significantly when the knee is fully extended.¹⁸ A quadruple complex is formed by the iliotibial band, the LCL, the popliteal tendon, and the biceps tendon.⁵

Anterior stability, which prevents forward displacement of the tibia on the femur, is provided primarily by the ACL and secondarily by the medial ligaments and the lateral structures, coupled with the support of the capsule. The quadriceps mechanism, particularly the vastus medialis, mechanically advantaged by the patella, acts as an extensor of the knee, as well as providing additional anterior stability.^{4,14}

The prime posterior stabilizer is the PCL, which provides its maximal resistance to deformation in the anteroposterior plane at 90° of flexion.^{14,19} This stability is augmented by the posterolateral capsule, the popliteal tendon, and also the lateral capsular structures. However, the latter are of significance only when the integrity of the PCL is interrupted. The popliteous contributes largely to the posterior stability due to a connection to the tibial insertion of the PCL via the posterior capsule.⁵

The musculature that controls rotation and stabilization in all positions, as well as assisting in flexion of the knees, is divided into two groups. Anteriorly, the sartorius and gracilis muscles exert their action just medial to the medial collateral ligament with the knee in flexion, while posteriorly the semimembranosus and semitendinosus muscles exert force on the posterior region of the medial femoral condyle.

Rotation of the knee occurs about a longitudinal axis parallel to the tibia. Flexion and extension occur about a transverse axis.

Tibiofemoral articulation

Simplistically, the knee can be regarded as a hinge joint. However, rotation occurs about a longitudinal axis parallel to the tibia as well as flexion and extension about a transverse axis. The knee has a normal active range of motion from 0° to 5° of hyperextension through to 140° to 150° of flexion (with the hip flexed). A further 10° to 20° of flexion is attainable passively.

A range of flexion is limited by the muscle bulk of the posterior thigh and the calf. Certain athletes with slim builds, for example ballet dancers, gain an extra 10° to 15° of active flexion. With the knee in a flexed position, 20° of medial rotation and 30° of lateral rotation are possible. An extended knee rotates very little.^{15,20}

Flexion and extension at the knee occur about a transverse axis through the femoral condyles to the tibia, and move anteriorly during extension and posteriorly during flexion. The movements of extension and flexion are associated with the “screw-home” movement, which provides a position of greater stability. These

movements are enabled by the complex geometric configuration of the joint surfaces and the ligamentous restraints within the knee.

The lateral femoral condyle is slightly longer and broader than the medial femoral condyle, and its longitudinal axis is in a more sagittal plane. During flexion and extension movements, the condyles roll or glide on the tibia depending on the position of the joint and the ligamentous restraints guiding these movements. The lateral femoral condyle is more mobile than the medial condyle, and, as such, the longitudinal axis of rotation is medially displaced about the medial tibial spine.⁵

The tibial plateau comprises the two tibial condyles, separated by the tibial spines. Although both condyles are convex superiorly in the transverse plane, in the sagittal plane, the medial condyle is concave superiorly, while the lateral condyle is convex superiorly. The incongruity of the femoral condyles on the tibial plateau is restored by the menisci, which are wedge-shaped in cross section.

As the knee flexes and extends, the femoral condyles roll, slide, and spin on the tibial plateau. The proportion of rolling versus sliding on the plateau is governed by the relative tensions of the cruciate ligaments in the different positions of the knee.^{2,9,15,20-22}

When the knee is fully extended, the bulk of the ACL is tight, whereas the major portion of the posterior cruciate is loose.¹⁵ With the onset of flexion, the bulk of the ACL relaxes, and for the first 15° to 20° of flexion, the femoral condyles roll back on the tibia. The posterior cruciate then tightens and the femoral condyles roll and slide simultaneously on the tibial surface. This combination of movements occurs in much the same way that a car tire spins on a slippery surface while the car still moves forward. As the knee approaches the extreme of flexion, the sliding movement of the femoral condyles predominates.^{15,20,21}

In a fully flexed position, the posterior portions of the femoral condyles are lodged on the tibial condyles posteriorly. Both of the cruciate ligaments are twisted about themselves—the bulk of the ACL being loose—while the anterior portion, or major section, of the posterior cruciate is tight. The movements of the femoral condyles on the tibia during extension directly mirror those of flexion, that is, sliding up to 15°–20° of

flexion, and then as the posterior cruciate relaxes and the ACL tightens, the femoral condyles roll on the tibial plateau.

The terminal phase of extension of the knee joint is accompanied by external rotation of the tibia, with the condyles sliding on one another, locking the knee in the extended position and affording maximum stability. This so-called “screw-home” mechanism is guided and controlled primarily by the ACL. Conversely, initiation of flexion from this position involves internal rotation of the tibia thereby unlocking the joint.^{2,22} The clinical relevance of this is that any dysfunction of the cruciate ligaments results in a nonphysiological sliding range. This brings articular surfaces into contact, which are ill-adapted for such movement, and, due to abnormal stresses, leads to premature degeneration of the cartilage.

The menisci are dynamic structures and move posteriorly with extension. As the knee flexes and extends, the menisci are pushed back and forth by the femoral condyles in much the same way a slippery melon seed can be squeezed between two fingers. Active anterior displacement occurs as the patellomeniscal ligaments pull the menisci forward with the patella as it moves during extension. Due to the semimembranosus attachment to the posterior horn of the medial meniscus, contraction of this muscle causes a posterior displacement of the meniscus, whereas the lateral meniscus is pulled backwards by the popliteal muscle.^{2,5,19}

Axial rotation can occur with the knee in flexion as the tibial spines are clear of the intercondylar notch, where they lodge in extension to inhibit such rotation. The ability of the knee to rotate is crucial to maintenance of a balanced gait, especially when walking on uneven surfaces and during sporting activities. The lateral femoral condyle moves approximately twice as far as the medial femoral condyle during rotatory motion due to the medially displaced axis of rotation. The menisci follow the movements of the femoral condyles during rotatory movements. However, the shape of the menisci distorts about their fixed points of attachment as they are pushed and pulled. It is during rotatory movements that many injuries to the menisci occur, primarily when they

fail to follow the condyles and become trapped between the opposing articulating surfaces.

Patellofemoral joint

The patellofemoral joint formed by the articular cartilage of the posterior patella and the femoral groove enables the smooth gliding of the patella in a longitudinal plane as the knee flexes and extends.^{23,24}

With the knee in an extended position, the patella rests superior to the femoral groove. The patella moves inferiorly with flexion and engages at 20°–30° in the femoral groove. Further, flexion increases the contact of the patella on the femur and at 120° of flexion, the superior aspects of the patellar facets make contact with the inferior region of the femoral groove, just superior to the notch. Flexion to 135° presents the odd facet medially and the superolateral region of the lateral facet laterally to the femoral articulating surface.²⁴ During rotational movements, the patella moves in a frontal plane relative to the tibia—laterally with internal rotation, and medially with external rotation.²⁰

Conclusion

The mechanism of knee injury is interrelated with the anatomy—both structural and functional—of the knee. This joint is the largest, most complicated synovial joint in the body. Movement, including rotation, flexion, and extension, is dependent upon a complex series of movements and mechanisms, involving several different aspects of the knee and thigh. Due to these factors and its unique position—between the body's two longest mechanical levers—the knee joint is at risk for injury from acute traumatic, subacute, or chronic overload conditions. The diagnosis and consequent treatment of injury correlates to the site of trauma and the articulations that are impaired.

The article in the series, "Diagnosing Knee Injuries: Patient History and Physical Examination," provides a guide for determining the nature of knee injury and assessing the extent of the injury.

REFERENCES

1. Baugher WH, White GM. Primary evaluation and management of knee injuries. *Orthop Clin North Am* 1985;16(2):315.
2. Gray H. *Anatomy of the human body*. 30th ed. Philadelphia: Lea & Feiber, 1985;346.
3. Hughston JC, Andrews JR, Cross MJ, Moschi A. Classification of knee ligament instabilities: part I. The medial compartment and cruciate ligaments. *J Bone Joint Surg Am* 1976;58-A:159.
4. Hughston JC, Andrews JR, Cross MJ, Moschi A. Classification of knee instabilities: part II. The lateral compartment. *J Bone Joint Surg Am* 1976;58-A:173.
5. Kaplan EB. Some aspects of functional anatomy of the human knee joint. *Clin Orthop* 1962;23:18.
6. Noyes FR, Grood ES, Butler DL, Raterman L. Knee ligaments test: what do they really mean? *Phys Ther* 1980;60(12):1578.
7. Ghosh P, Taylor TKF. The knee joint meniscus: a fibrocartilage of some distinction. *Clin Orthop* 1987;224:52.
8. Noble J, Turner PG. The function, pathology and surgery of the meniscus. *Clin Orthop* 1986; 210:62.
9. Palmer I. On the injuries to the ligaments of the knee joint: a clinical study. *Acta Chris Scand* 1938;53(suppl):11.
10. Ricklin P, Ruttiman A, Del Buono MS; Mueller KM, trans. *Meniscus lesions*. New York: Grune and Stratton, Inc, 1971;2.
11. Arnoczky SP, Adams M, DeHaven K, Eyre D, Mow V. Meniscus. In: Woo SL-Y, Buckwater JA, eds. *Injury and repair of the musculoskeletal soft tissues*. Park Ridge, Ill: American Association of Orthopedic Surgeons, 1987;487.
12. Arnoczky SP, Warren RF. Microvasculature of the human meniscus. *Am J Sports Med* 1982;10(2):90.
13. Shim S-S, Leung G. Blood supply of the knee joint: a microangiographic study in children and adults. *Clin Orthop* 1986;208:119.
14. Butler DL, Noyes FR, Grood ES. Ligamentous restraints to anterior posterior drawer in the human knee. *J Bone Joint Surg Am* 1980;62-A:259.
15. Girgis FG, Marshall JL, Al Monajem ARS. The cruciate ligaments of the knee joint. Anatomical, functional and experimental analysis. *Clin Orthop* 1975;106:216.

16. Hughston JC, Eilers AF. The role of the posterior oblique ligament in repairs of acute medial (collateral) ligament tears of the knee. *J Bone Joint Surg Am* 1973;55-A:923.
17. Ellman MH. Diagnosis and management of bursitis. *Compre Ther* 1984;10(8):14.
18. Andrews JR, Axe MJ. The classification of knee ligament instability. *Orthop Clin North Am* 1985;16(1):69.
19. Nielson S, Ovesen J, Rasmussen O. The posterior cruciate ligament and rotatory knee instability: an experimental study. *Arch Orthop Trauma Surg* 1985;104:53.
20. Kapandij IA. The physiology of the joints. Vol 2. 2nd ed Edinburgh: Churchill Livingstone, 1970;72.
21. Kennedy JC, Weinberg HW, Wilson AS. The anatomy and function of the anterior cruciate ligament: as determined by clinical and morphological studies. *J Bone Joint Surg Am* 1974; 56-A:223.
22. Smilie IS. Injuries of the knee joint. 4th ed. Edinburgh: Churchill Livingstone, 1975;29.
23. Aglietti P, Insall JN, Walker PS, et al. A new patella prosthesis. *Clin Orhop* 1975; 107:175.
24. Goodfellow J, Hungerford DS, Zindel M. Patellofemoral joint mechanics and pathology. I. Functional anatomy of the patellofemoral joint. *J Bone Joint Surg Br* 1976;56-B:287.